

# Diamond Knives

Are they the clear choice for clear corneal cataract surgery?

BY CHARLES H. WILLIAMSON, MD

**W**hen I converted my cataract surgery practice entirely to the use of the clear corneal technique under topical anesthesia in early 1992, I did so because I quickly embraced its advantages. The technique eliminated a number of steps in scleral surgery such as traction sutures, conjunctival incisions, scleral cautery, and conjunctival closure. I performed all surgery from a temporal incision. Because I was already creating 3-mm sutureless incisions for foldable IOLs, the transition was easy for me.

When it was first introduced, clear corneal surgery excited the ophthalmic community and gained widespread popularity. There were also early reports of wound leaks, endophthalmitis, and other surgical complications, however. This news was contrary to my own experience of fewer complications and zero cases of endophthalmitis in 15 years of clear corneal surgery. In recent years, new reports of leaking wounds, hypotonous eyes,<sup>1</sup> and increased rates of endophthalmitis<sup>2</sup> have surfaced and fueled a re-examination of clear corneal techniques.

This article discusses some of the issues ophthalmologists need to consider when performing clear corneal surgery, such as the materi-

als currently used to produce ophthalmic blades, their effect on the incisions made, and the related surgical outcomes.

## MOVING TO CLEAR CORNEAL INCISIONS

To successfully transition to clear corneal incisions, the surgeon must closely examine the wound's placement, architecture, sealing, and healing. Regarding the creation of the corneal tunnel, temporal incisions of 3 mm or less that are square (or nearly square) are the most stable and refractively neutral<sup>3,4</sup> (Figure 1).

## WHY USE DIAMOND KNIVES?

I had extensive experience with RK surgery with corneal wounds and subsequent healing. History is often our best teacher, and it made sense to me to look at my RK experience when moving my cataract surgery incisions from the sclera into the clear cornea. I could easily apply the lessons I learned from my days of RK. Accuracy, reproducibility, and wound healing are paramount in generating successful results with corneal incisions. All three of these areas showed significant improvement when the incisions were made using dia-

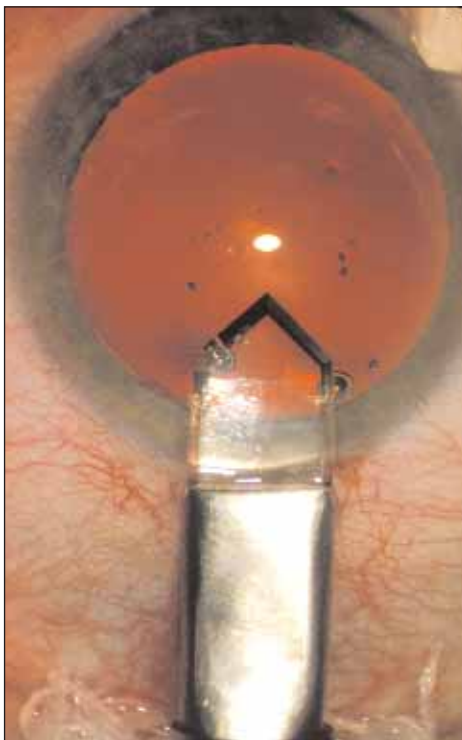


Figure 1. The author constructed a square clear corneal wound.

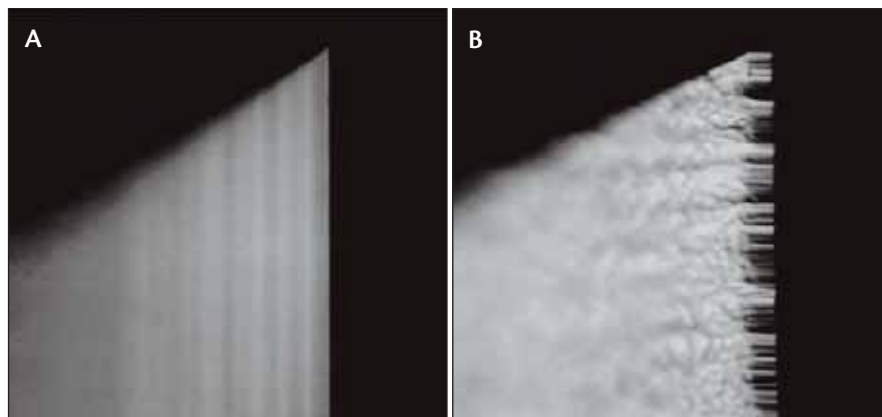


Figure 2. A diamond blade (A) has a much smoother edge than the deposition of chemical vapor of a black diamond blade (B).

mond versus steel blades. For these reasons, I transitioned directly to diamond knives when I started doing clear corneal cataract surgery. I collaborated with Ron Dykes of Diamatrix in The Woodlands, Texas, to create the first trapezoidal blade to reduce the stretching of the wound. I believe that the diamond blade and the new knife designs of knives are significant factors in the excellent surgical results I have achieved. Because the type of blade surgeons use to create clear corneal incisions is important for surgical outcomes, they should consider comparing blade materials, manufacturing techniques, and their effects upon the wound's creation before choosing a knife.

### BLADES FOR MICROSURGERY

#### Materials and Manufacturing Techniques

During the past several decades, manufacturers have used a variety of materials, including diamond, sapphire, black diamond, ceramic composites, and stainless steel, and techniques to produce microsurgical blades. Here are some observations that I have made.

#### Sharpness

When diamonds or other crystals (sapphire, ruby, etc.) are used for surgical blades, two manufacturing techniques are employed. The first is honing or lapping technology that was developed and is primarily used in the US and Europe. With this technology, the harder the material, the sharper the blade. Diamond is the hardest material known to man and therefore produces the sharpest edge (Table 1). Diamond blades also are produced using lasers and acid to etch the edges. This process was

developed in Russia and is more economical than the lapping technology. The major drawback with the cheaper technique is that surgeons cannot maintain the blades themselves and must replace them if they become damaged. Both techniques produce an exquisitely sharp edge. The blade's sharpness, in my experience, has obvious benefits; a sharper blade gives the surgeon more control, reduces trauma to the tissue, and creates more reproducible incisions.

Black diamond blades are not made of true diamonds or a synthetic diamond-like material. They are the product of the deposition of chemical vapor. This technique, along with the material used in the manufacturing process, produces a jagged versus a honed edge (Figure 2) that incises the cornea with a sawing action rather than the cleaving action of diamond blades.

The quality of the materials and the techniques used to produce stainless steel microsurgical blades have improved the design and sharpness of these devices, but there is still some variation among models and manufacturers. These variations can be troublesome and potentially hazardous in surgery. As demonstrated by the Mohs Scale of Hardness (Table 1),<sup>5</sup> stainless steel lacks the primary attribute that enables a blade to have a superior edge. There is no doubt that the latest technology, coining and chemical etching, produces a far superior blade than grinding. Most of the blades on the market today are produced using this process. Regardless of the grade of stainless steel or

TABLE 1. THE MOHS SCALE OF HARDNESS CONSISTS OF 10 CLASSIFICATIONS

Hardness†	Mineral or Substance	Absolute Hardness
6	Stainless steel	72
8	Hardened steel	200
9	Corundum (sapphire, ruby, etc.)	400
10	Diamond	1,500

†1 is the softest, and 10 is the hardest.



Figure 3. The Williamson trapezoid diamond keratome.

the manufacturing technique, stainless steel will not produce a blade as sharp as a diamond keratome.

Currently, manufacturers are developing ceramics and ceramic composites that may or may not equal the sharpness of a diamond blade's edge. In the past, these materials were limited because they could not be easily formed into blades for microsurgery.

### Penetration

The hardness or rigidity of the material used in a microsurgical blade can affect the knife's mass, which in turn can affect its penetration. As the hardest material, diamond lends itself to producing thin blades (less mass) while retaining rigidity. A diamond blade is limited, however, because it requires wider facets to produce an edge than coined metal does. Diamond blades are between 150 and 200  $\mu\text{m}$  thick. Because coined metal blades are relatively soft, their minimum thickness is approximately 150  $\mu\text{m}$ . Until a new material is developed, the 150- $\mu\text{m}$  threshold applies to most blades. We must rely upon geometry to create a better penetrating blade. Here again, diamond has an advantage over other materials. Because of a diamond blade's sharper edge, the angle of attack need not be as acute. Metal blades compensate for being less sharp by producing a more acute angle, which requires a longer blade. In other words, the shorter diamond blade does not enter the anterior chamber as far as a metal knife. The former therefore has a lesser chance of damaging adjacent ocular structures and has a greater margin of safety.

A blade's geometry not only affects the knife's penetration but also the incision's geometry. While working with Mr. Dykes to design a blade that met my requirements, I developed the 2.7- X 3.2-mm trapezoidal large-bevel-up-small-bevel-down design (Figure 3). This blade's geometry creates a smaller internal and a larger external incision. With

this design, the wider external incision produces an oarlock effect that reduces striae during cataract removal and facilitates the introduction of instruments into the anterior chamber. The smaller internal incision promotes a more secure wound and a stable anterior chamber. The beveled design creates a self-planning and self-sealing incision. I continue to use this design today, although I have reduced the blades' dimensions to 1.9 X 2.5 mm.

### Cost Effectiveness of Different Materials

In today's climate of reduced reimbursements, the cost per case becomes a paramount issue for a practice's profitability. If the features and benefits of all blades were equal (which they are not), surgeons' choice of tools could be based solely on their cost per case. Using this premise and making some assumptions, one can look at the numbers for a keratome. The cost of a diamond keratome  $\$2,800 \times 3 = \$8,400$ . An average yearly repair costs \$1,200. The total cost for the first year is \$9,600. An average of 2,000 cataract surgeries per year brings the cost per case for the first year to \$4.80 and \$0.60 per case for the following years. A premium single-use metal keratome prices at \$28. If one can use this type of blade three times, the average cost per case is \$9.30. A metal blade's performance is usually impaired if it is used more than three times.

A surgeon who uses metal blades can potentially lose \$9,000 in the first year and \$17,400 for each year thereafter. This same case can be made for blades made of other materials, which would yield similar results. The fact remains that "diamonds are forever."

### CONCLUSION

In the final analysis, it is the musician, not the music, that determines the level of excellence. Surgeons should choose a blade design or material that works best for you and your patient. For me, it is still diamond. ■

*Charles H. Williamson, MD, is CEO/Medical Director at the Williamson Eye Center in Baton Rouge, Louisiana. He acknowledged no financial interest in the products or companies mentioned herein. Dr. Williamson may be reached at (225) 924-2020; rdunn@williamsoncenters.com.*



1. Shingleton BJ, Wadhvani RA, O'Donoghue MV, et al. Evaluation of intraocular pressure in the immediate period after phacoemulsification. *J Cataract Refract Surg.* 2001;27:524-527.
2. Masket S. Is there a relationship between clear corneal cataract incisions and endophthalmitis? [editorial]. *J Cataract Refract Surg.* 2006;32:1556-1559.
3. Ernest PH, Lavery KT, Kiessling LA. Relative strength of scleral corneal and clear corneal incisions constructed in cadaver eyes. *J Cataract Refract Surg.* 1994;20:626-629.
4. Masket S, Belani S. Proper wound construction to prevent short-term ocular hypotony after clear corneal incision cataract surgery. *J Cataract Refract Surg.* 2007;33:383-386.
5. American Federation of Mineralogical Societies, Inc. Mohs scale of mineral hardness. Available at: [http://www.amfed.org/t\\_mohs.htm](http://www.amfed.org/t_mohs.htm). Accessed on May 15, 2007.